

FREQUENCY OF ANATOMICAL VARIATIONS OF NOSE AND PARANASAL SINUSES IN CLINICALLY SUSPECTED RHINOSINUSITIS PATIENTS BY COMPUTERIZED TOMOGRAPHY



Shahla Mohammed Rasul ^a, Kawa Abdullah ^a and
Tania Abubakr Ali ^b

Submitted: 1/8/2017; Accepted: 12/8/2018; Published 15/10/2018

ABSTRACT

Background

The anatomy of the nasal cavity and paranasal sinuses differs significantly, certain distinct variations are found most frequently among the general population. This makes CT scan an important preoperative investigation in the diagnoses and treatment of rhinosinusitis.

Objectives

To evaluate the types and frequency of anatomical variants in the nose and paranasal sinuses depicted by computed tomography (CT) in patients with chronic rhinosinusitis.

Patients and Methods

This study conducted on 76 patients with clinically suspected chronic rhinosinusitis whose age range from 12–77 years, 31 Males and 45 Females. CT scan were done for them in Sulaimani Teaching Hospital/ Department of Radiology, from March 2016 to September 2016.

Results

In this study, there were 375 variations which were divided on 27 types of variants, 6 of them were more common and represented 66 % of all variations, they were (1) agger nasi cells 79%, (2) nasal septal deviation 78%, (3) concha bullosa 58%, (4) septal spur 46%, (5) onodi cells 36%, (6) anterior clinoid pneumatization 32%. The other 21 less common variants formed 34 %. We found significant association between anterior clinoid pneumatization and optic canal dehiscence, also between incidence of atelectatic uncinate process and maxillary sinus hypoplasia.

Conclusion

The most frequent variations where those involved ethmoidal sinus, nasal septum and middle turbinates, particularly agger nasi cell, nasal septum deviation and concha bullosa.

Keywords: *CT scan, Anatomical variations, Agger nasi cell, Aeptal deviation, Concha bullosa.*

^a Department of Surgery, College of Medicine, University of Sulaimani.

Correspondence: shahla.rasul@univsul.edu.iq

^b X-Ray Center, Ministry of Health, Directorate of Sulaymaniyah.

INTRODUCTION

Although the nasal anatomy varies significantly among individuals, certain anatomic variations are common in the general population and are often seen more frequently in patients with chronic inflammatory disease. The significance of an anatomic variant is determined by its relationship to the ostiomeatal channels and nasal air passages. The ability of the variation to obstruct the air passages may imply a role in the development and recurrence of sinusitis⁽¹⁾.

Computed tomography (CT) is currently the modality of choice in the evaluation of the paranasal sinuses and adjacent structures. Its ability to optimally display bone, soft tissue and air, facilitates accurate depiction of anatomy and extent of disease in and around the paranasal sinuses. In contrast to standard radiography, CT can clearly show the fine bony anatomy of the ostiomeatal channels.

The optimal time to perform CT is during quiescent phase of the disease, which means after the maximum medical treatment. This diminishes the effect of acute inflammation and allows identification of specific anatomic areas of narrowing or disease. Patients should therefore undergo comprehensive medical therapy before they undergo CT².

The aim of this study is to evaluate the types and frequency of anatomical variants in the nose and paranasal sinuses of patients with clinically suspected chronic rhinosinusitis by computed tomography (CT).

PATIENTS AND METHOD

This prospective study carried out in sulaimaniya teaching hospital –X ray center from march 2016 to September 2016.

The study conducted on 76 patients suffering from chronic rhinosinusitis referred by otorhinolaryngologist for CT scan of nose & para nasal sinuses. Patients were scanned when they were clinically well between bouts of sinusitis.

For tomographic study SOMATOM Emotion (Siemens medical systems) 2011, 16 slice multi detector CT (MDCT) scanner was used.

In all cases, standard studies of the Sino-nasal region were performed. Axial image were done with the patient in supine position; coronal and sagittal image

were reconstructed from the axial images. all images were dedicatedly evaluated by the same radiologist with fifteen years of experience .

Direct scans with 5 mm in thickness were made, from inferior maxilla to the upper end of frontal sinus in scout view. Then reconstruction of coronal and sagittal images was done by 0.75-1mm slice in thickness.

The exclusion criteria included:

1. Those patient with history of trauma to the face.
2. Patient suffering from tumors of head and neck.
3. Those patient with history of nasal surgery.
4. Acute inflammatory conditions.

Statistical Analysis

Statistical Package for Social Sciences (SPSS) version 22, which is a statistical software program, and Microsoft excel spreadsheets (2013) were used for data entry, calculations, and data interpretations. Descriptive statistics and up-to-date statistical methods were used in the evaluations. Two sample t-test was used to determine the level of significances of association between different groups. P-values ≤ 0.05 were considered statistically significant.

RESULTS

Of 76 patients (45 were female and 31 were male).The age range was 12-77 years with the mean age (32.6 years). The highest percentage reported for age group was group 26-40(45%), followed by age range group 12-25 (30%).

According to the anatomical location, in percentage,the highest degree of variability was for ethmoidal air cells (32%) followed by nasal septum (25%), then turbinates (15%), sphenoid sinus (15%), maxillary sinus (7%) and least one is frontal sinus (5%), Figure 1.

Regarding the site of affection, (375) sites affected by 27 types of variations in the nasal cavity and paranasal sinuses), the highest degree for 6 most common individual variations were as following; (1) agger nasi cell 79 %, (2) nasal septal deviation 78%, (3) concha bullosae 58 %, (4) nasal spur 46% , (5) onodi cell 36%, (6) anterior clinoid pneumatization 32%,and this 6 variants represent about 67% of all variations and the remaining other 21 variants represent only 33%, Table 1.

Nasal septum

Our study included any nasal septal deviation from the midline (59 cases 78%). The rest of the variations found were septal bony spurs (35 cases 46%) and nasal septal pneumatization(1 cases 1%). We see that there is no significant difference between male and female sex groups (P- values >0.05). Also there is no significant difference between age subgroups (P- values >0.05).

Turbinates

Fifty eight variants were encountered at turbinates, in order of frequency, concha bullosa (44 cases,58%) ,paradoxical middle turbinates (9 cases, 12%) , pneumatized superior turbinate (3 cases, 4%), hypoplasia of the turbinates (2cases, 3%); There is no significant difference between male and female for turbinate variations and also no significant difference between age subgroups (P- values >0.05). There is insignificant association between incidence of septal deviation and concha bullosa with P- Value 0.52.

Ethmoid sinuses and Uncinate process

Among 120 variants observed the most common was agger nasi (60 cases ,79%), followed by onodi cells (7 cases, 58%) and the least one was aerated crista galli (2 cases, 3%).

There is insignificant difference between male and female except for agger nasi cells which show significant difference (P-Value 0.048).

Maxillary sinus

In the present study ,most common variation was maxillary sinus septa (18%) , followed by accessory Ostia 9% then maxillary sinus hypoplasia 3% & the least were maxillary sinus overpneumatization with infraorbital nerve dehiscence in which each case was only 1%.

Frontal sinus

In our study frontal sinus hypoplasia was commonest variant (among frontal sinus variation) about 9 cases followed by overpneumatized 7 cases and frontal sinus agenesis.

Sphenoid sinus

Among sphenoid sinus variation , largest number was pneumatized anterior clinoid process 24 cases followed by optic canal dehiscence 14 and sphenoid overpneumatization also 14 cases then least 2 variant were hypoplastic sphenoid 3 cases followed by pneuntization of posterior clinoid 2 cases as seen in Table 2 and Figure 2.

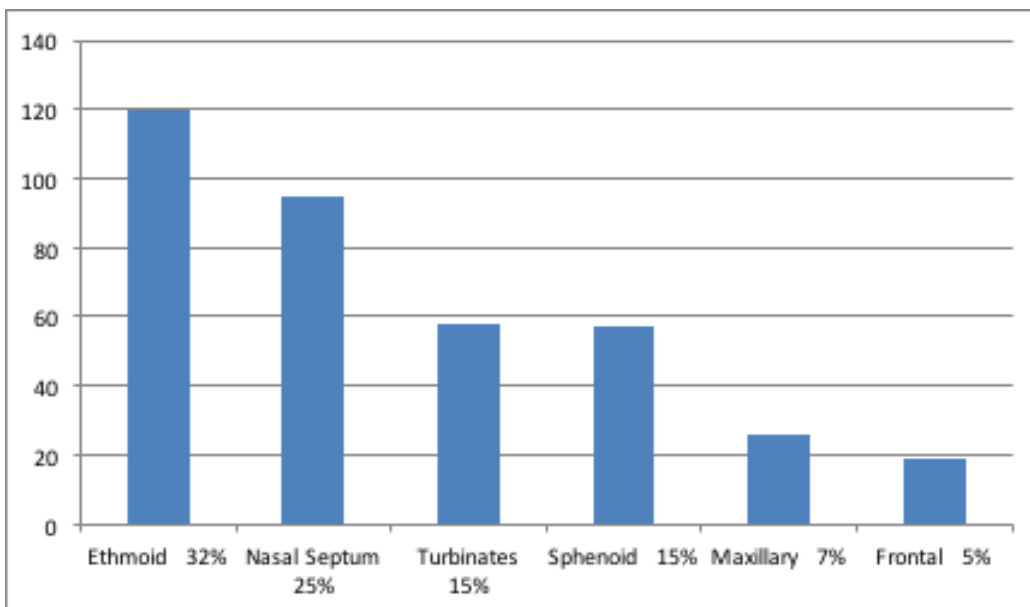


Figure 1. Frequency and Percentage of sinus variations by the anatomical locations (n=76, Total Number of Variations=375).

Table 1. Common Variation frequency, percentages, and sides.

Variation		Side	Frequency	Percentage
Agger nasi cell	Valid	Right	9	12%
		Left	18	24%
		Bilateral	33	43%
		Total	60	79%
	absent		16	21%
	Total		76	100%
Nasal Septum Deviation	Valid	Right	35	46%
		Left	24	32%
		Total	59	78%
	absent		17	22%
	Total		76	100%
Concha Bullosae	Valid	Right	9	12%
		Left	8	11%
		Bilateral	27	36%
		Total	44	58%
	absent		32	42%
	Total		76	100%
Nasal Spur	Valid		35	46%
	absent		41	54%
	Total		76	100%
Onodi Cells	Valid	Right	4	5%
		Left	16	21%
		Bilateral	7	9%
		Total	27	36%
	absent		49	64%
	Total		76	100%
Pneumatized Anterior Clinoid	Valid	Right	8	11%
		Left	5	7%
		Bilateral	11	14%
		Total	24	32%
	absent		52	68%
	Total		76	100%

Table 2. Association between incidence of anterior clinoid pneumatization and optic canal dehiscence (Grades II & III).

		Optic canal dehiscence		p-value
		(+)	(-)	
Pneumatized Anterior Clinoid	(+)	10	14	0.001*
	(-)	4	48	

*There is a significant association (P-value<0.05)

DISCUSSION

A wide range of anatomical variations prevalence were presented differently in various studies that it could be the result of discrepancies in analyzing and studying methods, definitions, racial varieties and the accuracy of studies according to CT scan cut offs.

The fact that our study involves those cases suspected to have chronic rhino sinusitis, so the results simply are different from those done on general population or those of control groups.

We found 375 variants in 76 patients which were belong to 27 types of variations in the nasal cavity and paranasal sinuses but the highest percentage cases affected by 6 most common variations were as follows: 1) Agger nasi cell 79%, 2) Nasal septal deviation 78%, 3) Concha bullosae 58 %, 4) Nasal spur 46%, 5) Onodi cell 36%, 6) Anterior clinoid process pneumatization 32%.

Our study results are approximately near to results of Thimmappa et al ⁽³⁾ in the order of frequency of most common variations, they reported Agger nasi in 68% ,as the most common ,followed by Septal deviation 47% ,Concha bullosa 37%.while Jain P. K et al ⁽⁴⁾ noticed that deviated nasal septum was the most common variation in (78.8%) followed by middle concha bullosa in (32.7%) patients. Bolger et al ⁽⁵⁾ reported Agger nasi 98.5%, concha bullosa 53%, and nasal septal deviation 18.8%.

Nasal septum variations

We reported septum deviation in (59 cases, 78%) and this was concordance with the result of Aramani A ⁶ (74%) and Kaygusuz A⁷ (72.3%), but differ from Maru ⁽⁸⁾ (55.7%) and this difference in prevalence may be due to different criteria used for the degree and morphologic features of septal deviation.

Our study shows septal deviation more in female (45 cases) than male (31cases) but the difference is not significant, (P- values >0.05).

This is different from the result of Mundra et al ⁽⁹⁾ which reported male (34 cases) more affected than female (27 cases) and the deviation was predominantly on the left (59%) side. This difference from our research may be due to exclusion of those patients who have history of trauma to nose which is more frequent in males.

Also the septal deviated more to the right (46%) than

the left (32%), this is differ from study of kumar et al ⁽¹⁰⁾ that showed slight predominance to the left side (29%) as compared to right side (23%).

In the present study we found septal bony spurs (35 cases, 46%) and this was near to result of Earwaker ⁽¹¹⁾ reported septal spur in 34% of cases while jain P.K ⁽⁴⁾ reported 12.7% in his study.

Also we reported nasal septum pneumatization (1 cases, 1%), this was near to the result of K Dua et al ⁽¹²⁾ which were reported in 1 patient (2%).while Thimmappa TD et al ⁽³⁾ reported pneumatization of the septum in 30% , this wide range of prevalence may be due to different definition of pneumatization, some investigator regarded extension of the sphenoid sinus to the posterior part of the septum as pneumatization of the septum while other exclude those cases.

Turbinates

In the present study, concha bullosa was observed in 44 cases (58), and this is nearly goes with the result of Bolger⁵ (53.6%) and Scribano et al ⁽¹³⁾ (67%). While Maru ⁽⁸⁾ reported in 42.6 % of cases and Kaygusuz A ⁽⁷⁾ reported in 41.5% of cases.

We noticed that there is considerable variation in the reported prevalence of concha bullosa, this may be due to using different criteria of pneumatization which used by different investigator and on the method of analyses. Some researcher accept very small amount of air as pneumatization for example: zerniech et al ⁽¹⁴⁾ encountered concha bullosa in 34% of patients employing a definition of concha bullosa as any degree of middle turbinate pneumatization on CT scan, this discrepancy to our study may be the result of using 4mm slice thickness in their study for interpretation & using old generation CT machine model at that time (1988) .

Other investigator considered extensive pneumatization as concha bullosa as in the study of Bolger ⁽⁵⁾. In addition the incidence depend on the patients group, as some studies including ours performed on patients with suspected chronic rhinosinusitis. Maru ⁽⁸⁾ reported 77% in the present of ostiomeatal disease, when compared to an incidence of 33% in the absent of the disease.

In our study paradoxical middle turbinate was found in 12% of cases. The incidence in other literatures were: 12% by Asruddin et al ⁽¹⁵⁾, 12.5% by Sheetal D et al ⁽¹⁶⁾, 13.8% by Kaygusuz A ⁽⁷⁾ and 15% by Lloyd ⁽¹⁷⁾ .

Ethmoidal sinus and uncinat process:

Agger nasi cells were present in (79%) in our study. Result in other literatures were : 64.6% by Kaygusuz A⁷ , 88.5% by Maru⁽⁸⁾ and 98.5% by Bolger⁽⁵⁾. The reported prevalence in different series ranges widely from 2% in Lloyd⁽¹⁷⁾ to 98.5% Bolger⁽⁵⁾, corresponding to varying anatomic definitions. Kennedy and zenreich (1988)⁽¹⁸⁾ noted agger nasi cells in nearly all patients evaluated, this would suggest that the agger nasi cell is a part of normal anatomy.

Onodi cell were found in our study 27 cases 36% . This is near to the results of A. Chmielik⁽¹⁹⁾ 39,8% While Kasemsiri P⁽²⁰⁾ reported the incidence of onodi cells 49.5%. Kainz and Stammberger⁽²¹⁾ found onodi cells in 42% using endoscopic dissection, which was higher than that observed with CT examination (39%). A. Chmielik et al⁽¹⁹⁾ suggested that both axial and coronal plane reconstructions of the CT examinations should always be used to detect and describe the onodi cell properly like our study.

Haller cells incidence in our study was (12%). Lloyd⁽¹⁷⁾ reported 15%, Zinreich⁽¹⁸⁾ 10% and Kaygusuz A⁽⁷⁾ 13.8%, but it was less than that reported by Bolger⁽⁵⁾ 45.9% and Maru⁽⁸⁾ 36% ,the possible reasons for this discrepancy is difference in interpretation of haller cell, sample study or in the technique of CT scanning.

We observed Uncinate process pneumatization in (12%). Our result was concordance with earwaker⁽¹¹⁾ 9.1%, Wani et al⁽²²⁾ in (14%) patients, Bolger et al⁽⁵⁾ reported in 2.5%, and Adeel et al⁽²³⁾ in 5.2%

Atelectatic uncinat process was seen in (7%). Tulli et al observed in 2%⁽²⁴⁾ and Anita Aramani 9.3%⁽²⁰⁾. There is significant association between incidence of Atelectatic Uncinate Process and Maxillary Sinus Hypoplasia with (p- value 0.002) this is goes with the result of Tamer Erdem⁽²⁵⁾ and A De Sousa⁽²⁶⁾. We observed over pneumatized Ethmoidal Bulla in 11%, zinreich et al⁽¹⁸⁾ reported 8% which is close to our result and Llyod⁽¹⁷⁰⁾ reported in 17 % . While Arun⁽²⁷⁾ observed in (37.33%) patients. Patel AK et al⁽²⁸⁾.Reported prevalence of large ethmoid bulla in 32.66% patients. Fadda GL et al⁽²⁹⁾ and Krzeski A et al.⁽³⁰⁾ reported large ethmoid bulla in 32.8% and 26.75% patients respectively.

This discordance between these results may be due to different description of giant ethmoidal bulla, some investigators depend on the measurement of the cell, while others depend on the evidence of extension of this cell to osteomeatal complex.

Maxillary sinus variations

Hypoplasia in our study was detected in 4% of cases and this was concordance with the result of Aramani et al⁶ which reported 2% and Bolger et al⁽⁵⁾ found in 10.4%. Maxillary sinus septation was found in 18% in our study. In the review of the literatures; Ulm et al⁽³¹⁾ found in 18.3%, Kumar et al⁽²⁴⁾ in 19.6%, Krenmmair et al⁽³²⁾ in 16% Won-Jin Lee⁽³³⁾ observed in (24.6%), Velasquez-Plata et al⁽³⁴⁾ in 24%.

Hyperpneumatized maxillary sinus in our study was 1%, Kalavagunta et al.⁽³⁵⁾ observed in 8%. Accessory ostia was 9% in our study and this was concordant with the result of A. Sindel et al⁽³⁶⁾ (13.8%) but Yenigun, et al⁽³⁷⁾ reported in 19.1 %.

Dehiscence of infra orbital nerve was 1% of cases. Lang J. observed dehiscence of bony margins of the infraorbital nerve canal up to 14% of cases⁽³⁸⁾ also Yenigun, A et al⁽³⁹⁾ reported in 12.3% but their sample size were larger and they used different description of infra-orbital dehiscence .

Frontal sinus variations

We observed frontal sinus hypoplasia in (12%) , over pneumatization seen in (9%) and agenesis in (4%) . Our result relatively near to the result of the A. Guerram et al⁽⁴⁰⁾ who reported hypoplasia in 9.4% agenesis in 2.5% and hyper pneumatization in 11.9% . Earwaker J⁽¹¹⁾ observed that hypoplasia in 4% and agenesis in 5% of the population, while Nesibe et al⁽⁴¹⁾ reported ; hypoplasia in 14.2%, aplasia in 4.1%, and hyperplasia 44.5 %.

Sphenoid sinus variations

We observed anterior clinoid process pneumatization in 32% this is compatible to the result of Heskova et al⁽⁴²⁾ (26.5%),. but Bolger⁽⁵⁾ reported in 13.3%. We found overpneumatized sphenoid sinuses in 18% of cases .this is comparably near to the result of Hamid et al (15.9%) while A. SĖirikci et al⁽⁴³⁾ and Citardi MJ⁽⁴⁴⁾ reptoted 29.3% and 37.5% respectively.

We reported sphenoid sinus hypoplasia in 4%. E. Sanverdi⁽⁴⁵⁾ reported in 3% Kayalioglu et al⁽⁴⁶⁾ 1.9% and in M. PAIS Clemente⁽⁴⁷⁾ 2%. The grade of optic canal dehiscence was as follows: grade 1 (82%), grade 2 (12%), grade 3(7%), grade 4 (0%), this result nearly goes with the result of Delano and zenreich 1996⁽⁴⁸⁾ grade 1 (76%), grade 2 (15%), grade 3 (6%) and grade 4 (3%).

In our study there was significant correlation between optic canal dehiscence (grade 2 and 3) and anterior clinoid pneumatization with p value 0.001, this is compatible with the result of Delano⁽⁴⁸⁾, so pneumatization of anterior clinoid process is an important indicator that the optic nerve may be at risk of injury during sinus surgery because of the frequent association with the type 2 and type 3 nerve configurations.

Delano⁴⁸ stated that in general, the greater the aeration of the sinus, the greater the likelihood of optic canal dehiscence.

Clinical significance of variations

The review of the literature showed that the clinical significance of the anatomical variants of the nose and PNS is controversial. Most authors agree that many anatomic variations can contribute in some way to the development of recurrent sinusitis. Zinreich (1993)⁽⁴⁹⁾ found that 62% of his patients had at least one anatomic variant, against 11% in the normal control group. These findings seem to suggest a correlation or clinical significance of anatomical variants regarding the appearance of inflammatory sinus pathology.

However, Bolger et al⁽⁵⁾, in a series of 202 patients, observed (64.9%) anatomical variants, but found the incidence in patients with sinus pathology was similar to that in persons studied for other reasons. while Yousem⁵⁰ claimed that the variants may be a predisposing factors, depending on their size, location, or the amount of mucosal contact caused by the variations.

Of all the anatomical variants of Lloyd's series¹⁷ only the concha bullosa was associated with a high incidence of sinusitis (85%).

Also Kennedy, bolger⁽⁵⁾ and zinreich⁽⁴⁾ agreed that certain anatomic variations increase the risk of complications during FESS so a preoperative display of the individual patient's anatomy on CT, allows anatomic variations to be taken into account by the surgeon during FESS, thus decreasing the likelihood of any complications.

In conclusion, the most frequent variants are those involving the ethmoidal sinus, nasal septum and middle turbinates particularly agger nasi cell, nasal septum deviation and concha bullosa.

Pneumatization of anterior clinoid process is an important indicator that the optic nerve may be at risk of injury during sinus surgery because of the frequent association with the type 2 and type 3 nerve configurations.

We suggest a larger study sample on particular anatomical variants and relation between variation and extent of the rhinosinus diseases.

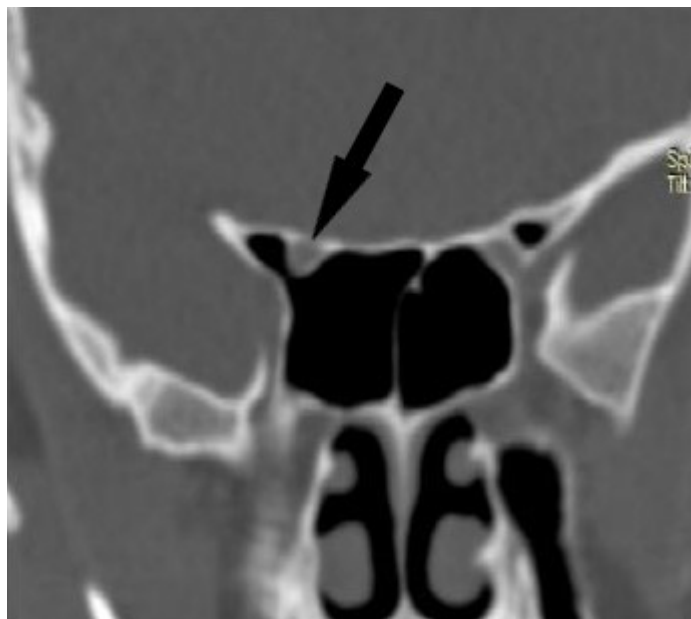


Figure 2. Coronal CT scan, optic canal dehiscence type 3.

REFERENCES

1. Nafi Aygun, S. James Zinreich. Radiology of the Nasal Cavity and Paranasal Sinuses. In: Paul W. Flint, Bruce H. Haughey, Valerie J. Lund, John K. Niparko, Mark A. Richardson, K. Thomas Robbins, J. Regan Thomas (Eds). Cummings Otolaryngology Head & Neck Surgery .5th ed :Philadelphia; Mosby Elsevier ; 2010. p. 1923 , 1935.
- 2 Donald C, Lanza David W, Kennedy. endoscopic sinus surgery .in: Byron J., Bailey , Karen H., Calhoun , Gerald B., Md. Healy , Harold C., Iii, Md. Pillsbury , Jonas T., Md. Johnson , M. Eugene, Jr., Md. Tardy , Robert K, Md. Jackler (Eds). Otolaryngology Head & Neck Surgery - Otolaryngology (3th ed) : texas ; Lippincott Williams & Wilkins. 2001 p.273.
3. Thimmappa T.D , Amith P, Nagaraj M, Harsha K.N, Gangadhar K.S, Abdul Azeem. Anatomical variations of sinonasal region: a CT scan study . International Journal of Research in Medical Sciences :2014 Nov;2(4):1441-1445
4. Jain P. K., Arora N, Kumar A, Hemant Mishra. Computed Tomographic Evaluation of anatomical variations of paranasal sinus region and their clinical importance. Earthjournals..2014;3(4):269
5. Bolger WE, Butzin CA, Parsons DS. Paranasal sinus bony anatomic variation and mucosal abnormalities: CT analysis for endoscopic sinus surgery. Laryngoscope 1991;101:56-64
6. Anita Aramani, R.N. Karadi, and Saurabh Kumar. A Study of Anatomical Variations of Osteomeatal Complex in Chronic Rhinosinusitis Patients-CT Findings. J Clin Diagn Res. 2014 Oct; 8(10): KC01-KC04
7. Kaygusuz A, Haksever M, Akduman D, Aslan S, Sayar Z. Sinonasal anatomical variations: their relationship with chronic rhinosinusitis and effect on the severity of disease-a computerized tomography assisted anatomical and clinical study. Indian J Otolaryngol Head Neck Surg. 2014 Sep;66(3):260.
8. Maru YK, Gupta V. Anatomic variations of the bone in sinonasal CT. Indian Journal of Otolaryngol and Head Neck Surgery. 2001; 53:123-128.
9. R. K. Mundra, Yamini Gupta, Richi Sinha, and Alaknanda Gupta. CT Study of Influence of Septal Angle Deviation on Lateral Nasal Wall in Patients of Chronic Rhinosinusitis. Indian J Otolaryngol Head Neck Surg. 2014 Jun; 66(2): 187-190.
10. Pradeep Kumar, Rakesh BS, Rajendra Prasad .Anatomical Variations of Sinonasal Region: A Coronal CT Scan Study. international journal of contemporary medical research. September 2016;3(9):2601-2604
11. Earwaker J. CT of Paranasal sinuses. RadioGraphics. 1993; 13:381-415
12. K Dua, H Chopra, AS Khurana, M Munjal. CT Scan Variations in Chronic Sinusitis. Ind J Radiol Imag 2005 ;15:3:315-320
13. Scribano E, Ascenti G, Loria G, et al. The role of the ostiomeatal unit: anatomic variations in inflammatory disease of the maxillary sinuses. Eur J Radiol 1997;24:172-431.
14. James Zinreich, Thaddafus Gotwald. Radiographic anatomy of the sinuses. In: David W. Kennedy, William E. Bolger, S. James Zinreich (Eds) . diseases of the sinuses diagnoses and management 1st ed . Hardcover : London; 2001 p.14,15,19.
15. Asruddin , Yadav SPS, Yadav RK, Singh J. Low dose CT in chronic sinusitis. Indian J Otolaryngol Head Neck Surg. 2000;52: 17-21 .
16. Sheetal D, Devan P P, Manjunath P, et al .CT PNS: Do we really require before FESS?. Journal of Clinical & Diagnostic Research. April 2011;5:179-181
17. Lloyd GAS. CT of the paranasal sinuses: study of a control series in relation to endoscopic sinus surgery. J Laryngol Otol 1990; 104:477-81
18. Zinreich SJ, Mattox DE, Kennedy DW, et al. Concha bullosa: CT evaluation. J Comput Assist Tomogr 1988;12:778-84
19. A. Chmielik, L. Chmielik, R. Boguslawska-Walecka; Warszawa PL. The prevalence and CT detection of Onodi cell types. European society of radiology. 2014
20. Kasemsiri P1, Thanaviratnanich S, Puttharak W. The prevalence and pattern of pneumatization of Onodi cell . J Med Assoc Thai. 2011 Sep;94(9):1122-6
21. Kainz J, Stammberger H. Danger areas of the posterior rhinobasis. An endoscopic and anatomical-surgical study. Acta Otolaryngol. 1992;112(5):852-861
22. Asif A. Wani Sohit Kanotra Mohammad Lateef Rafiq Ahmad Sajad M. Qazi Shawkat Ahmad .CT scan evaluation of the anatomical variations of the ostiomeatal complex. Indian J Otolaryngol Head Neck Surg (July-September 2009) 61:163-168
23. Adeel, M., Rajput, M. S., Akhter, S., Ikram, M., Arain, A., Khattak, Y. J. (2013). Anatomical variations of nose and para-nasal sinuses; CT scan review. Journal of the Pakistan Medical Association 2013;63(3):317-319
24. Isha Preet Tuli, Subhadrata Sengupta, Sudeep Munjal, Santosh Prasad Kesari, Suvamoy Chakraborty

- .Anatomical Variations of Uncinate Process Observed in Chronic Sinusitis. *Indian J Otolaryngol Head Neck Surg*(April-June 2013) 65(2):157-161
25. Tamer Erdem, Davut Aktas , Gulnur Erdem , murat cem Miman , Orhan Ozturan. Maxillary sinus hypoplasia Article in *Rhinology* 2002;40(3):150-3 .
26. A De Sousa, M Sandra, A Salas, F Medina. Maxillary silent sinus syndrome: A retrospective review of 18 cases. *The Internet Journal of Otorhinolaryngology*. 2008 Volume 10 Number
27. Arun Kumar Patel, Aruna Patel, Brijesh Singh, Subhash Chand Jain. "Anatomical Variations in Sinonasal Region in Cases of Sinus Headache - CT Scan - PNS Study". *Journal of Evidence based Medicine and Healthcare*. 2015;2(32): 4709-4718. DOI: 10.18410/jebmh/2015/662
28. Patel AK, Patel A, Singh B, Sharma MK. study of functional endoscopic sinus surgery in patients of sinus headache. *IJBMR* 2012; 3(3):1924-30.
29. G.L. Fadda, S. Rosso, S. Aversa, A. Petrelli, C. Ondolo, G. Succo. Multiparametric statistical correlations between paranasal sinus anatomic variations and chronic rhinosinusitis. *ACTA otorhinolaryngologica italica*. 2012;32:244-251
30. A Krzeski, E Tomaszewska et al. Anatomic variations of the lateral nasal wall in the computed tomography scans of patients with chronic rhinosinusitis. *American Journal of Rhinology* 2001 ;15 :(371-375)
31. Ulm CW, Solar P, Krennmair G, Matejka M, Watzek G. Incidence and suggested surgical management of septa in sinus-lift procedures. *Int J Oral Maxillofac Implants*. 1995;10:462-465
32. Krennmair G, Ulm CW, Lugmayr H, Solar P. The incidence, location, and height of maxillary sinus septa in the edentulous and dentate maxilla. *J Oral Maxillofac Surg*. 1999;57:667-671
33. Won-Jin Lee, Seung-Jae Lee, Hyoung-Seop Kim. Analysis of location and prevalence of maxillary sinus septa. *J Periodontal Implant Sci*. 2010 Apr; 40(2): 56-60. DOI: 10.5051/jpis.2010.40.2.56
34. Velasquez-Plata D, Hovey LR, Peach CC, Alder ME. Maxillary sinus septa: a 3-dimensional computerized tomographic scan analysis. *Int J Oral Maxillofac Implants*. 2002;17:854-860
35. Sudhakiran Kalavagunta and K.T.V. Reddy. Extensive maxillary sinus pneumatization. *United Kingdom Rhinology*. 2003; 41 113-117.
36. Alper Sindel, Murat Turhan, Eren Ogut, Mehmet Akdag, Asli Bostanci, Muzaffer Sinde: An endoscopic cadaveric study: Accessory maxillary ostia: *Dicle Medical Journal* doi:10.5798/diclemedj.0921.2014.02.0413
37. Yenigun A, Fazliogullari Z, Gun C, Uysal II, Nayman A, Karabulut AK: The effect of the presence of the accessory maxillary ostium on the maxillary sinus. *Eur Arch Otorhinolaryngol*. 2016 Jun 14.
38. Lang J. *Clinical anatomy of the nose, nasal cavity and paranasal sinuses*. New York: Thieme Medical Publishers; 1989
39. Yenigun, A., Gun, C., Uysal, I.I. et al. Radiological classification of the infraorbital canal and correlation with variants of neighboring structures. *Eur Arch Otorhinolaryngol* (2016) 273: 139-144. doi:10.1007/s00405-015-3550-8
40. Amine Guerram, Jean-Marie Le Minor, Stephane Renger, and Guillaume Bierry: Brief Communication: The Size of the Human Frontal Sinuses in Adults Presenting Complete Persistence of the Metopic Suture: *AMERICAN JOURNAL OF PHYSICAL ANTHROPOLOGY* 2014;154:621-627 .
41. Nesibe Gu'Yu'ksel Aslier , Nuri Karabay, Gu'ls_ah Zeybek, Pembe Keskinog'lu :The classification of frontal sinus pneumatization patterns by CT-based volumetry . . France .Springer-Verlag. 2015
42. Heskova G , Mellova Y, Holomanova A, Vybohova D, Kunertova L, Marcekova M, Mello M: Assessment of the relation of the optic nerve to the posterior ethmoid and sphenoid sinuses by computed tomography: *Biomed Pap Med Fac Univ Palacky Olomouc Czech Repub*. 2009 Jun;153(2):149-52.
43. A. S_irikci A, Bayaz_ot Y.A, Bayram M, Mumbu_ç S, G_ung_ör K, Kanl_ökama M. Variations of sphenoid and related structures. *Eur. Radiol*. 2000. Springer-Verlag
44. Citardi M J , Gallivan R P, Batra P S, Maurer CR Jr, Rohlfing T, Roh HJ, Lanza DC. Quantitative computer-aided computed tomography analysis of sphenoid sinus anatomical relationships. *Am J Rhinol*. 2004 May-Jun;18(3):173-8.
45. Sanverdi E, Berker M, Akcalar S. The importance of sphenoidal sinus pneumatization in the endoscopic transsphenoidal surgery planning; evaluation in a series of 628 patients. *European society of radiology* 2013
46. Gulgun Kayalioglu , Erturk M, Varol T. Variations in sphenoid sinus anatomy with special emphasis on pneumatization and endoscopic anatomic distances. *Neurosciences* January 2005; 10(1):79-84 .

47. M. Pais Clemente Surgical Anatomy of the Paranasal Sinus. In. Howard L. Levine M. Pais Clemente (Eds). Sinus Surgery Endoscopic and Microscopic Approaches .stuttgart, New York: thieme; 2005.p 7,12,15,17,18.
48. Mark C. DeLano, F. Y. Fun, and S. James Zinreich 1996 : A CT Anatomic Study Relationship of the Optic Nerve to the Posterior Paranasal Sinuses: AJNR Am J Neuroradiol 17:669-675
49. Zinreich S. Imaging of inflammatory sinus disease. Otolaryngol Clin North Am 1993;26:535-54766
50. Yousem DM. Imaging of sinonasal inflammatory disease. Radiology 1993;188:303-314.